

The Use of Platelet-Rich Plasma in Arthroscopy and Sports Medicine: Optimizing the Healing Environment

Emilio Lopez-Vidriero, M.D., Ph.D., Krista A. Goulding, M.D., David A. Simon, M.D., Mikel Sanchez, M.D., and Donald H. Johnson, M.D., F.R.C.S.C.

Abstract: Platelet-rich plasma (PRP) is a new technology focused on enhancing the healing response after injury of different tissue types. PRP is prepared by withdrawal of patients' peripheral blood and centrifugation to obtain a highly concentrated sample of platelets, which undergo degranulation to release growth factors with healing properties. It also contains plasma, cytokines, thrombin, and other growth factors that are implicated in wound healing and have inherent biological and adhesive properties. The prepared concentrate is then injected back into the patient at the site of morbidity. This may be intralesional, intra-articular, or surrounding the involved tissue bed. PRP preparations have been used therapeutically in various medical fields from implantology to vascular ulcers, with a more recent evolution and promising results in the field of sports medicine and arthroscopy. Sports medicine patients desire a rapid return to their preinjury level of function, and PRP may have certain applications that will speed recovery in cases of tendon, ligament, muscle, and cartilage disorders. In particular, anterior cruciate ligament reconstruction has shown better autograft maturation, improved donor site morbidity, and pain control, in addition to improved allograft incorporation. By acceleration of the biological integration of the graft by use of PRP, patients may undergo faster, more intensive rehabilitation programs and return to sports more rapidly. Because of its autogenous origin, easy preparation, and excellent safety profile, the advent of PRP has opened another therapeutic door for sports medicine physicians and orthopaedic surgeons. Future directions of PRP include improving the results of arthroscopic and related surgery, in addition to delineating correct dosage, timing, and quantification, as well as ideal techniques of PRP application.

Platelet-rich plasma (PRP) is a general term for new technologies that are focused on enhancing the healing response after injury of different tissue types. To understand PRP's mechanism of action and possible

applications, it is important to be familiar with the general healing response. General healing follows a pathway that begins with inflammation lasting days, continues with cellular and matrix proliferation for weeks, is followed by tissue formation and maturation for months, and ultimately, finishes with tissue remodeling, which takes years.¹ PRP preparations contain high concentrations of platelets that, once activated, undergo degranulation to release growth factors with healing properties.² They also contain plasma and other growth factors implicated in wound healing, in addition to thrombin, which has inherent biological and adhesive properties.³

The basic mechanism for preparing PRP involves withdrawal of the patient's peripheral blood, followed by centrifugation to obtain a concentration of platelets and cytokines well above serum baseline.³ However, there are differences between commercial systems with respect to the preparation protocol, number of

From the Department of Orthopaedics, The Ottawa Hospital (E.L.-V., K.A.G., D.A.S.), Ottawa, Ontario, Canada; Arthroscopy Division, Clínica La Esperanza (M.S.), La Esperanza, Spain; and Department of Orthopaedic Surgery, University of Ottawa (D.H.J.), Ottawa, Ontario, Canada.

Supported by Fundación Caja Madrid. The authors report no conflict of interest.

Received September 15, 2009; accepted November 18, 2009.

Address correspondence and reprint requests to Krista A. Goulding, M.D., Department of Orthopaedics, The Ottawa Hospital, 501 Smyth Rd, RM CCW 1637, Ottawa, Ontario K1H8L6, Canada.

E-mail: kristagoulding@hotmail.com

© 2010 by the Arthroscopy Association of North America

0749-8063/10/2602-9539\$36.00/0

doi:10.1016/j.arthro.2009.11.015

platelets, use of anticoagulant, inclusion of leukocytes, and use of activators that may lead to very different biological effects in application.⁴ Understanding these differences is critical when analyzing published results and deciding which system to use.

PRP preparations have been used therapeutically in various medical fields, from implantology⁵ to vascular ulcers,⁶ with good results. Sports medicine is an evolving field in which patients desire and require rapid recovery after injuries. Although there has been a tremendous evolution in surgical techniques and instrumentation, the medical approaches of the sports medicine physician have primarily remained oral, topical, and injectable anti-inflammatories. Because of its autogenous origin, easy preparation, and excellent safety profile, the advent of PRP has opened another therapeutic door for sports medicine physicians.

There is increasing interest in the application of PRP preparations in arthroscopic and related surgical procedures around the world. By acceleration of the biological integration of the graft by use of PRP, patients could undergo faster, more intensive rehabilitation programs and return to sports more rapidly, as compared with patients treated with traditional surgical protocols.

TISSUE HEALING PROCESS

As outlined previously, the general healing response is a pathway beginning with inflammation and cellular and matrix proliferation, followed by tissue formation and maturation, with each phase lasting for days, weeks, and months, respectively. In this context, optimal tissue healing requires “an exquisitely designed continuum of events that are interdependent and subject to both intrinsic and extrinsic signaling.”⁷

After tissue injury, the healing continuum begins with the inflammatory phase. This phase requires an adequate blood supply that will attract macrophages and form a fibrin clot at the injured site to provide a provisional scaffold for those platelets trapped in the clot. The fibrin clot provides contact guidance and a conductive surface onto which cells can migrate and proliferate. Platelets trapped in the provisional scaffold are the primary reservoir of growth factors. These growth factors are derived from platelet granules, serum, and local cells.⁷

The cellular and matrix proliferation stage is critical because cells are the metabolic engine that drives tissue repair.⁸ These cells usually originate from pluripotent stem cells in adjacent tissues (e.g., infrapatellar fat pad for anterior cruciate ligament [ACL] and satellite cells for muscle).⁸ They are recruited to the

area by a variety of growth factors with chemotactic and mitogenic functions that stimulate further cellular and vascular proliferation.¹

The tissue formation and maturation phase is driven by cell phenotype and local environmental factors that are both biological and physical.¹ Finally, tissue remodeling is the longest stage and can last for years. During this phase, the repaired tissue is remodeled through normal physiologic turnover in response to loading, stress, and humoral factors.¹ The final appearance and function of the formed tissue depend on various factors and interactions affecting the different phases. The resulting tissue may be fibrous nonfunctional tissue (scar), repaired partially functional tissue, or newly formed completely functional tissue.⁷

The healing response may be augmented or stimulated by use of endogenous agents or exogenous stimuli. Inflammation and matrix proliferation can be enhanced by the introduction of growth factors (e.g., PRP), scaffolds, and/or mesenchymal stem cells.⁷ In the maturation and remodeling phases, probably the most important external stimulus is enhancing mechanobiological signaling by means of rehabilitation⁷ and physical therapy.

The role of growth factors is to work with other molecules to modulate cell function. Specifically, growth factors interact with the extracellular domain of transmembrane receptors that transduce secondary signals to control subcellular biology.⁹ The potential benefits of many of the growth factors have been shown: platelet-derived growth factor is a powerful mitogen for connective tissue cells; transforming growth factor β is not only morphogenic but is also strongly implicated in collagen synthesis; type I insulin-like growth factor is critical for cell survival, growth, and metabolism; and the cooperative actions of vascular endothelial growth factor (VEGF) and hepatocyte growth factor induce endothelial cell proliferation and migration, thus initiating the angiogenic response.⁹

WHAT IS PRP?

The first descriptions of the development and use of PRP were in the early 1990s, when science was focused on developing new “biological glues.” PRP preparations were potent glues because of their high proportions of fibrin, and they were primarily used in maxillofacial surgery. Surgeons and scientists observed that these preparations had bone-forming properties, as well as anti-inflammatory and antibacterial effects.^{10,11} The effects were attributed mainly to

TABLE 1. *Properties of PRP*

“Biological glue”
Coagulation and hemostasis
Wound healing
Provisional scaffold for stem or primary cell migration and differentiation
Intra-articular restoration of hyaluronic acid
Balances joint angiogenesis
Increases glycosaminoglycan chondrocyte synthesis and cartilage matrix
Anti-inflammatory
Antibacterial
Analgesic

NOTE. PRP has multiple properties, including antibacterial and anti-inflammatory effects, coagulation, and hemostasis, as well as analgesic properties. PRP contains platelets that secrete alpha granules. These granules are made up of growth factors (platelet-derived growth factor, transforming growth factor β , VEGF), endostatin, platelet factor 4, angiopoietins, and thrombospondin 1, which are all active in wound healing. Fibrin also contributes to the creation of a scaffold for wound healing and allows PRP to function as a biological glue.

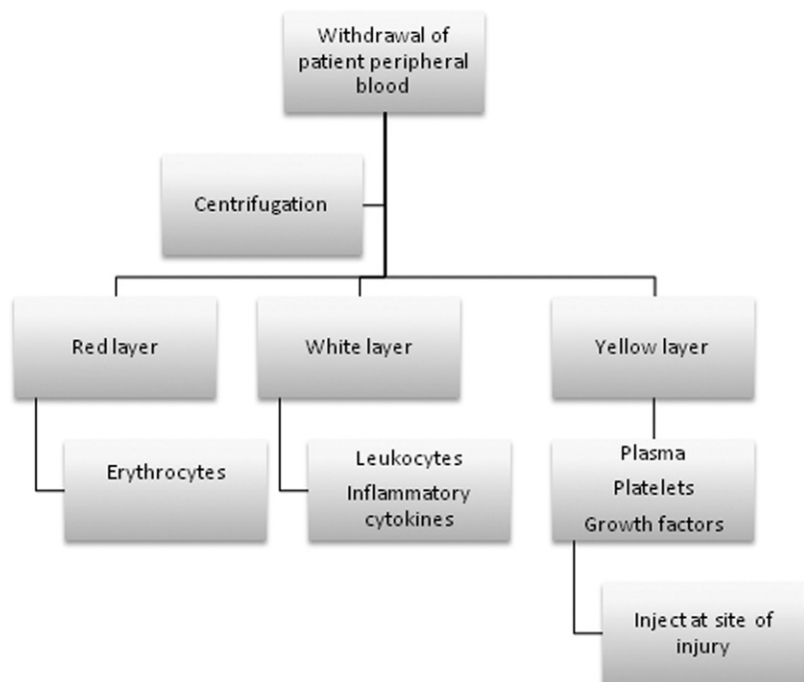
platelets, which are anuclear cells that circulate in peripheral blood for 7 to 10 days. Aside from their role in coagulation and hemostasis, platelets contain alpha granules with various molecules that are secreted upon activation. These molecules are growth factors (platelet-derived growth factor, transforming growth factor β , VEGF), endostatin, platelet factor 4,

angiopoietins, and thrombospondin 1. All are involved in the healing process.² Moreover, platelets have been identified to have analgesic properties by releasing protease-activated receptor 4 peptides.¹² However, PRP contains not only platelets but also plasma with fibrin and other growth factors that influence healing. Fibrin acts as a provisional scaffold for stem or primary cell migration and differentiation, and it functions as a biological glue¹³ (Table 1).

All PRP preparations have certain steps in common (Fig 1). The basic mechanism for preparing PRP involves withdrawal of the patient’s peripheral blood (Fig 2A), followed by centrifugation (Fig 2B) to obtain a concentration of platelets and cytokines well above serum baseline. The centrifuged product is usually stratified into 3 layers in its container (Fig 2C). The base, named the red layer, is filled with erythrocytes; the middle, or white layer, contains leukocytes and inflammatory cytokines; and the top, or yellow layer, is filled with plasma, platelets, and growth factors. The selected part of the prepared concentrate is then injected into the region where it is required. This may be intralesional (as in the muscle), intra-articular (as in ACL reconstruction), or surrounding the involved tissue bed (e.g., within the Achilles tendon sheath after rupture repair).

Several commercial products exist (Table 2), with minor but important differences that may impact bio-

FIGURE 1. Preparation of PRP. PRP is withdrawn peripherally from the patient (approximately 10 mL) and placed in a centrifugation machine. After centrifugation, 3 layers are evident within the sample. The red layer contains erythrocytes, and the white layer contains leukocytes and other inflammatory cytokines; these 2 layers are discarded. The yellow layer is the uppermost layer, and it contains plasma, platelets, and other growth factors. It is then injected at the site of injury.



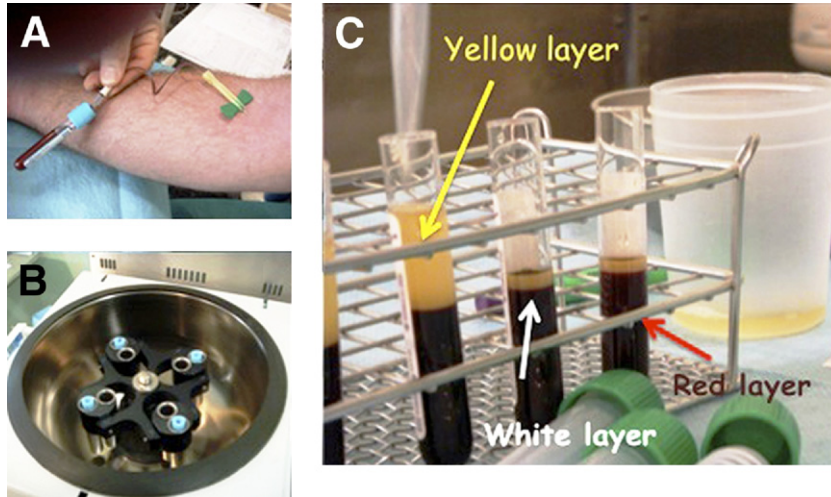


FIGURE 2. The basic mechanisms for preparing PRP involve (A) withdrawal of the patient's peripheral blood and (B) centrifugation to obtain a concentration of platelets and cytokines. (C) The centrifuged product is stratified into 3 layers.

logical efficacy. These subtle differences may be easily overlooked, and the surgeon should appreciate in detail the type of system being used, in the context of the desired endpoint and the tissue involved.

The use of the term "PRP" has been controversial. The generalized nature of the terminology is thought to be a potential hindrance to differentiating between the various products and their respective protocols. This raises concerns about potential uses of PRP because different products render different biologic effects.⁴ The main differences among the systems are as follows: the speed and number of centrifugations that lead to different platelet concentrations, the use of anticoagulant in the sample container, the presence of leukocytes in the preparation, and the use of an activator⁴ (Table 3). These factors should be

taken into account when one is analyzing the published results and when deciding which system to use.

A system that delivers a higher absolute number of platelets is not necessarily better. The number of platelets needed to obtain the optimal effect in bone regeneration has been shown to be between 503,000 and 1,729,000 platelets/ μL of PRP.¹⁴ Concentrations below 3.8×10^5 platelets/ μL have a suboptimal effect, and concentrations above 1.8×10^6 platelets/ μL may have a paradoxically inhibitory effect.¹⁴

As previously mentioned, the activation of platelets is required to release growth factors from the alpha granules. Some commercial systems do not activate their preparations, with the argument that these will be activated once in the surgical field. Others use exogenous or endogenous thrombin to activate the PRP,

TABLE 2. Characteristics of Main PRP Commercial Protocols Available

System	Blood Volume	Procedure	Time	Final Volume of PRP	Final Platelet Concentration	Leukocytes	Activator
ACP-DS (Arthrex, Naples, FL)	9 mL	Single spin	5 min	3 mL	$\times 2\text{-}\times 3$	No	None
Fibrinet (Cascade; Musculoskeletal Tissue Foundation)	9-18 mL	Single spin (for PRP) Double spin (for PRFM)	6 min (PRP) 6 min + 15 min (PRFM)	4-9 mL	$\times 1\text{-}\times 1.5$	No	CaCl_2
GPS (Biomet)	27-110 mL	Single spin	15 min	3-12 mL	$\times 3\text{-}\times 8$	Yes	AT/ CaCl_2
Magellan (Medtronic, Minneapolis, MN)	30-60 mL	Double spin	4-6 min	6 mL	$\times 3\text{-}\times 7$	Yes	CaCl_2
PRGF (BTI Biotechnology Institute)	9-72 mL	Single spin	8 min	4-32 mL	$\times 2\text{-}\times 3$	No	CaCl_2
SmartPrep (Harvest Technologies, Plymouth, MA)	20-120 mL	Double spin	14 min	3-20 mL	$\times 4\text{-}\times 6$	Yes	BT/ CaCl_2

Abbreviations: CaCl_2 , calcium chloride; AT, autologous thrombin; BT, bovine thrombin.

TABLE 3. Differences Between PRP Systems

Speed of centrifugation
Number of centrifugations
Use of anticoagulant
Presence of leukocytes in preparation*
Use of activator†

*Leukocytes may release matrix metalloproteinases (matrix metalloproteinase 8 or 9) and excessive reactive oxygen species, resulting in increased tissue damage.

†Calcium chloride may be used in conjunction with an activator (e.g., exogenous thrombin) to avert possible immune reactions.

before in vivo deposition. The use of exogenous thrombin may be considered an issue because of the possibility of adverse immune reactions.³ As such, calcium chloride has also been used as an activator to avoid the possibility of these side effects.³

The inclusion of leukocytes in the preparation is also controversial. The biological deleterious effects resulting from neutrophils containing matrix metalloproteinases 8 and 9³ have been well described. Moreover, neutrophils may increase tissue damage by releasing excessive amounts of reactive oxygen species in the inflammatory phase of muscle injury.¹⁵

APPLICATIONS OF PRP IN SPORTS MEDICINE

PRP systems have shown good results in various medical fields, from implantology⁵ to the treatment of vascular ulcers.⁶ Sports medicine patients want a rapid return to their preinjury level of function, and PRP may have certain applications that will speed recovery in cases of tendon, ligament, muscle, and cartilage disorders (Tables 4 and 5).

Tendons have low metabolic rates at baseline and are predisposed to slow healing after injury.⁹ Basic science studies have shown that co-cultures of tenocytes and a preparation rich in growth factors (PRGF; BTI Biotechnology Institute, Vitoria, Spain) increase the proliferation and secretion of VEGF and hepato-

TABLE 4. PRP Applications

PRP Applications	Examples
Chronic tendinosis	Tennis elbow
Tendinopathy	Chronic rotator cuff tendinopathy, jumper's knee
Acute tendon injury	Achilles tendon rupture, SLAP lesions
Osteoarthritis	Osteochondral defects
Muscle injury	Hamstrings tear
Osteochondritis	Osteochondritis dissecans lesions

TABLE 5. PRP Applications in Arthroscopy and Related Surgery

Arthroscopic Procedure	PRP Applications in Arthroscopy
ACL repair	Improves allograft integration within tunnel by limiting graft motion, decreasing osteolysis Decreases time to graft integration
Meniscal repair	Increases healing in zone of avascularity
SLAP repair	Accelerates healing times
Osteochondral defect repair	Augmentation of chondral body repair

cyte growth factor.¹⁶ This was shown to improve angiogenesis and lessen fibrosis after repetitive injection in the severed Achilles tendons of sheep.¹⁷ On the basis of encouraging results in cultures and animal models, Sanchez et al.¹⁸ performed a comparative study in athletes. They compared intraoperative PRGF injections in a group of Achilles tendon rupture repairs, with a matched control group treated with surgical repair alone. This study showed that the group that had surgery plus PRGF recovered significantly earlier and had a smaller cross-sectional area of fibrotic tendon after 18 months than the control group.

PRP has also proven to be effective in treating chronic tendinosis. Mishra and colleagues¹⁹ showed a significant reduction, at 8 weeks, in tennis elbow symptoms in a group treated with PRP compared with a control group (GPS System; Biomet, Warsaw, IN). A group from the Netherlands led by Gosen²⁰ has replicated this protocol and compared the PRP group with a group treated with cortisone injection for tennis elbow. They observed that the PRP group enjoyed better and faster functional recovery and pain relief after 6 months.

Chronic rotator cuff tendinopathy and partial- or full-thickness tears could be a potential target for treatment with PRP alone or in combination with physiotherapy and surgery. Anderson and colleagues¹⁹ observed that a cohort of patients treated surgically, in combination with platelet-rich fibrin matrix (PRFM), used significantly fewer narcotics for less than half the time of counterparts in a matched control cohort. In massive rotator cuff surgery, Maniscalco et al.²¹ have shown good results adding the Cascade membrane (A.T. Grade, Milan, Italy). Recently, Marcacci and colleagues²² at the Rizzoli Institute have studied the effects of PRP in jumper's knee (chronic refractory patellar tendinopathy) after previous classical treatments have failed. They observed significantly bet-

ter results in terms of Tegner, EuroQol, and visual analog scale scores and pain level compared with baseline and with controls treated with physiotherapy.

Muscle injuries have been treated successfully with the PRGF system (BTI Biotechnology Institute). The treatment protocol consists of extracting the early blood clot percutaneously under ultrasound control and then filling the gap with PRGF, again under ultrasound guidance. Sanchez et al.²³ found that 20 athletes had full recovery in half the expected time. Moreover, fibrosis was not apparent at long-term follow up, and no reinjuries occurred.

In fibrocartilage basic science studies have shown that the use of PRP enhances meniscal repair in the avascular region of rabbit menisci, both in vitro and in vivo at 12 weeks.²⁴ Clinically, Sgaglione and colleagues¹⁹ have explored the use of PRP to augment meniscal repairs and have found optimal and successful healing along with an 80% success rate in clinical outcomes (Tegner and Lysholm scores) of 40 young patients treated with meniscal repair and PRP. In addition, the use of PRP has been shown to accelerate healing and reduce pain in SLAP repairs as compared with controls.²⁵ Other fibrocartilage-like tissues, such as the hip labrum, are being surgically repaired in conjunction with PRP supplementation. Unfortunately, we are not aware of any published results to date.

Recent studies have shown good results where cartilage defects, osteochondritis, and osteoarthritis have also been treated with PRP. Sanchez et al.²⁶ used the PRGF system in combination with arthroscopic surgery to reattach a large chondral loose body (>2 cm) and observed accelerated complete articular cartilage healing. Moreover, in Spain the groups of Sanchez et al.²⁷ and Cugat²⁸ have used intra-articular injections of PRGF to treat knee osteoarthritis. PRGF has been shown to significantly decrease pain and improve quality of life and clinical outcomes, as compared with intra-articular hyaluronic acid supplementation.²⁹ This benefit could be explained by the effect of PRGF on restoring hyaluronic acid concentration and balancing angiogenesis in the joint.²⁹

Other PRP systems have been shown to increase glycosaminoglycan chondrocyte synthesis, as well as cartilage matrix, in rabbit models of osteoarthritis. Interestingly, the use of PRP suppressed the progression of osteoarthritis in the ACL-transected rabbit model, morphologically and histologically.³⁰

CLINICAL EXPERIENCE IN ACL RECONSTRUCTION WITH PRP

Success rates of ACL reconstruction surgery vary between 73% and 95%, and the rate of return to the preinjury level of activity varies from 37% to 75%.³¹ There has been increasing interest in improving these results, especially in the presence of graft failures. Return to full activity varies from 6 to 12 months because biological fixation is not strong enough to bear aggressive rehabilitation until 12 weeks after surgery.³¹

By acceleration of the biological integration of the graft by use of PRP, patients could potentially advance through more intensive rehabilitation programs and return to sports more rapidly than patients treated with traditional surgical protocols. This is of particular interest in terms of the timing of incorporation of soft-tissue grafts into the tunnel. The results have been varied; some reports suggest that allografts incorporate in the tunnel more slowly than bone-tendon-bone (BTB) grafts and show higher rates of failure, which could be attributed to their low cellularity.³² Conversely, a recent systematic review by Carey et al.³³, which evaluated 9 nonrandomized, prospective clinical trials comparing autograft with allograft, showed no difference between these 2 modalities at early clinical follow up (although 1 study with an allograft failure rate of 45%, suspected to be due to the sterilization process, was excluded). Nonetheless, promoting cell proliferation with PRP could purportedly shorten the healing time as well as the overall healing rate, thus decreasing the number of both allograft and autograft failures. In addition, complications limiting graft integration within the tunnel, such as graft motion and tunnel widening, could be avoided or improved with the use of PRP.

In North America there is an increasing interest in PRP technology. Fanelli and colleagues¹⁹ have reported their results using the Cascade PRFM system (Musculoskeletal Transplant Foundation, Edison, NJ) in ACL reconstructions with allografts. They found less tunnel expansion and osteolysis in patients who underwent supplementation with PRFM. They followed 70 ACL reconstructions, including 34 isolated ACL reconstructions, 30 ACL medial-side reconstructions, and 6 ACL lateral-side reconstructions. To avoid confounding factors, all reconstructions were performed with fresh-frozen allograft tissue from the same tissue bank, and the same methods and materials for fixation were used. Digital radiography showed that those patients treated with PRP had a 6.7% inci-

dence of tunnel expansion and osteolysis whereas those patients who did not undergo supplementation with PRP had a 52% incidence of this complication. Moreover, when they used PRP in combination with surgery for those patients with knees with ACL–medial collateral ligament (MCL) insufficiency, they found little or no inflammation and no wound breakdown or blisters at the MCL wound site. They also observed that there was normal skin tension just 5 days after surgery. Interestingly, there were no infections in knees treated with PRP. The authors attributed the improvement in static stability, measured by KT-1000 arthrometer (MEDmetric, San Diego, CA), to the improvement of collateral ligament wound healing.

The South American experience with PRP and ACL reconstruction has been led by Radice et al.³⁴ in Chile, who studied the healing process of the ACL-reconstructed knee on magnetic resonance imaging (MRI) studies. To evaluate the concordance of MRI with histology, they performed second-look arthroscopies at 6, 9, and 12 months to obtain graft samples from BTB ACL-reconstructed knees. They concluded that MRI characteristics mirror the histologic stages described by Arnoczky et al.⁸ At 6 months, the intra-articular portion of the graft was found to be hypointense, whereas the bone plugs were hyperintense with diffuse edema around the tunnels. This correlated with the stage of incorporation, with small, disorganized cells; high vascular proliferation; and low-frequency collagen patterns on histologic sections. At 9 months, the entire graft was hyperintense, with heterogeneous zones on MRI and a more homogeneous distribution of cells, better organization of collagen, and less vascularization histologically. Finally, at 12 months, the appearance of the graft was hyperintense, completely homogeneous, and without bone edema around the tunnels. This corresponded histologically to a normal ACL.

After determining the MRI characteristics of the healing ACL graft, Radice et al.³⁵ designed a prospective randomized trial involving 25 patients treated with ACL reconstruction in combination with PRP (GPS System [Biomet] with thrombin activator) and compared them with a control group comprising 25 patients who underwent surgery alone matched for age and gender. BTB autografts were used in 15 patients in each group, and hamstring autografts were used in the other 10 patients. In BTB autografts, 5 mL of activated PRP was added to an absorbable gelatin compressed sponge (Gelfoam; Pfizer, Ixelles, Belgium) and sutured to the femoral plug and intra-

articular parts of the BTB graft, acting as a scaffold. In hamstring autografts the sponge was placed between the folded tendons and sutured in the same manner. Five milliliters of thrombin-activated PRP was injected into the sponge in both scenarios.

Postoperatively, monthly MRI studies were performed from 3 to 9 months to track the homogenization curve of the intra-articular portion of the graft in the PRP group.³⁵ The control group was studied monthly between 6 and 12 months, assuming that homogenization of the graft does not occur before the sixth month as shown in the previous MRI study. The images were evaluated by a single radiologist in a blinded manner. The authors found that the time to complete homogeneity was 177 days for the group with surgery plus PRP, whereas the group with surgery alone required 369 days to acquire a matured graft. Moreover, when the subgroup of BTB autograft was analyzed, the maturation time in the PRP group was 109 days versus 363 days. In light of these results, Radice et al. concluded that the use of PRP accelerates graft maturation by half of the expected time, with an additional reduction in maturation time from 12 months to 3.6 months in the BTB graft and PRP group. These results are especially significant in light of the accelerated recovery time desired in sports medicine.

A similar study was performed in Portugal by Silva and Sampaio,³⁶ which showed different results. All surgeries were performed by the same surgeon, using double-bundle reconstructions with hamstring autografts. Forty patients were divided into four groups: a control group, a group with inactivated PRP injected within the tunnels, a group with activated PRP injected within the tunnels, and a group with inactivated PRP injected within the tunnels in addition to an intra-articular injection of inactivated PRP at 2 and 4 weeks postoperatively. The PRP system used was GPS (Biomet). However, the authors injected only 1.5 mL of PRP between the tendon strands in the tunnels without using any type of scaffold, and only in the fourth group did they use autologous heated thrombin as an activator (Clotalyt; Biomet). There was no reference to the quantity of PRP that was injected intra-articularly or whether it was activated. The authors performed MRI at 12 weeks to compare the signal intensity of the fibrous interzone in the femoral tunnels only, and they found no difference among the groups at 3 months. They concluded that the use of PRP, whether activated or not, does not change the healing process at 12 weeks. However, in analyzing these results, one should consider the limitations in

technique (no activation, no scaffold use or intratendinous injection), in sample size (underpowered study), and in the location of image analysis (no intra-articular tendinous analysis).

In Spain PRP preparations have been used since the early 1990s. Sanchez et al.⁹ have developed their own system, named "preparation rich in growth factors" (PRGF system III; BTI Biotechnology Institute).¹⁰ The term "PRGF" denotes 100% autologous and biocompatible products elaborated by use of a 1-step centrifugation process. Sodium citrate is used as an anticoagulant when peripheral blood is withdrawn. After centrifugation, a moderately elevated platelet concentration of 6×10^5 platelets/ μL is obtained. This concentration has been reported to induce the optimal biological benefit.¹⁴ In addition, leukocyte content has been eliminated from PRGF with the aim of avoiding the proinflammatory effects of the proteases and acid hydrolases contained in white blood cells. Lastly, calcium chloride is used as the activator. The addition of calcium chloride promotes the formation of native thrombin, mimicking the physiologic clotting process and enabling a more sustained release of growth factors. Moreover, using a standardized dose of calcium chloride, while avoiding the addition of exogenous thrombin, grants control over the liquid-gel (fibrin matrix) transformation and confers versatility to administration procedures.³⁷ Different formulations with therapeutic potential can be easily obtained depending on the degree of activation. The formulations include non-activated and activated liquid PRGF, scaffold-like PRGF composed of fibrillar and cellular components, and elastic, dense, and hemostatic fibrin.

This system has been widely used in Spain in different clinical contexts since 1990. ACL surgery supplemented with PRGF has been studied by the groups of Sanchez et al.³⁸ in Vitoria and Cugat²⁸ in Barcelona. Sanchez et al. compared a cohort of 50 patients (9 BTB and 41 hamstring autografts) treated with surgery plus PRGF with a cohort of 50 patients (11 BTB and 39 hamstrings) who had surgery alone matched for age and type of autograft. Their protocol was to soak the graft in activated liquid PRGF before passing it through the tunnels in the final stages of surgery. With the knee evacuated of fluid by means of arthroscopic aspiration, and once the graft was in place, they injected activated liquid PRGF inside the autograft, within the tunnels, and in the trochleoplasty. At the donor site, they used activated fibrin-dense PRGF to promote hemostasis and wound healing. They found that in the surgery-plus-PRGF group,

there were fewer severe postoperative hematomas and a drop in the need for forced manipulation to deal with a limited range of motion. There were also larger numbers of completely stable knees and better radiographic integration of the grafts within the tunnels in the first month postoperatively in this group. In addition, the authors had the opportunity to perform a repeat arthroscopy in one of the PRGF knees because of a meniscal tear, and they observed that the graft appeared to be completely integrated at 8 months.

Cugat²⁸ is performing a randomized controlled trial comparing the graft maturation rate of ACL-reconstructed knees with BTB autografts. One group underwent surgical repair supplemented with 8 mL of PRGF intra-articularly after fixation of the graft; the other group was managed with surgery alone. Preliminary results at the time of preparation of this article have indicated that, according to Radice's MRI grading,³⁴ graft maturation is completed in approximately half of the time in the group supplemented with PRGF, compared with surgery alone. Moreover, Cugat added the PRGF preparation to the patellar tendon gap and has observed, by ultrasound, faster recovery times, less postoperative pain, and faster gap filling at the tendon site.

The future of PRP techniques in ACL surgery is in the field of primary repairs. Although previous experience has shown that primary repair has a tendency to fail in humans, the possibility of augmenting and enhancing the biological environment for repair with PRP may open another door to less invasive procedures to achieve stability in the acute ACL-deficient knee. However, it is important to note that basic science studies with pig models have shown controversial results to this point.³⁹⁻⁴²

CONCLUSIONS

The use of PRP technologies has opened another door in the treatment of soft-tissue injuries. An understanding of the principles of tissue healing and the pathophysiology behind PRP, as well as a basic knowledge of the differences in commercial systems involved in the preparation of these products, is essential to the successful application of this modality in both the conservative and operative management of soft-tissue injury. Promising results have been shown in the fields of sport medicine and arthroscopy. Future directions include improving the results of arthroscopic procedures and related surgery—in particular, primary ACL reconstructions. Further research will also be aimed at delineating correct dosage, timing,

and quantification, as well as ideal techniques of PRP application.

Acknowledgment: The authors thank Dr. Seijas and Dr. Cugat, Department of Orthopaedics, Hospital Quiron, Barcelona, Spain.

REFERENCES

- Werner S, Grose R. Regulation of wound healing by growth factors and cytokines. *Physiol Rev* 2003;83:835-870.
- Anitua E, Andia I, Ardanza B, Nurden P, Nurden AT. Autologous platelets as a source of proteins for healing and tissue regeneration. *Thromb Haemost* 2004;91:4-15.
- Anitua E, Sanchez M, Nurden AT, Nurden P, Orive G, Andia I. New insights into and novel applications for platelet-rich fibrin therapies. *Trends Biotechnol* 2006;24:227-234.
- Anitua E, Sanchez M, Orive G, Andia I. Shedding light in the controversial terminology for platelet rich products. *J Biomed Mater Res A* 2009;90:1262-1263.
- Wojtowicz A, Chaberek S, Urbanowska E, Ostrowski K. Comparison of efficiency of platelet rich plasma, hematopoietic stem cells and bone marrow in augmentation of mandibular bone defects. *N Y State Dent J* 2007;73:41-45.
- Cervelli V, Gentile P, Grimaldi M. Regenerative surgery: Use of fat grafting combined with platelet-rich plasma for chronic lower-extremity ulcers. *Aesthetic Plast Surg* 2009;33:340-345.
- Arnoczky SP. Biologic adjuncts to connective tissue healing. Can we improve Mother Nature's recipe? In: Day AS, ed. *Las Vegas: AANA specialty day 2009*. Las Vegas: AAOS, 2009;101-107.
- Arnoczky SP, Tarvin GB, Marshall JL. Anterior cruciate ligament replacement using patellar tendon. An evaluation of graft revascularization in the dog. *J Bone Joint Surg Am* 1982;64:217-224.
- Sanchez M, Anitua E, Orive G, Mujika I, Andia I. Platelet-rich therapies in the treatment of orthopaedic sports injuries. *Sports Med* 2009;35:1-10.
- Anitua E. Plasma rich in growth factors: Preliminary results of use in the preparation of future sites for implants. *Int J Oral Maxillofac Implants* 1999;14:529-535.
- Bielecki TM, Gazdzik TS, Arendt J, Szczepanski T, Krol W, Wielkoszynski T. Antibacterial effect of autologous platelet gel enriched with growth factors and other active substances: An in vitro study. *J Bone Joint Surg Br* 2007;89:417-420.
- Asfaha S, Cenac N, Houle S, et al. Protease-activated receptor-4: A novel mechanism of inflammatory pain modulation. *Br J Pharmacol* 2007;150:176-185.
- Ahmed TA, Dare EV, Hincke M. Fibrin: A versatile scaffold for tissue engineering applications. *Tissue Eng Part B Rev* 2008;14:199-215.
- Weibrich G, Hansen T, Kleis W, Buch R, Hitzler WE. Effect of platelet concentration in platelet-rich plasma on peri-implant bone regeneration. *Bone* 2004;34:665-671.
- Tidball JG. Inflammatory cell response to acute muscle injury. *Med Sci Sports Exerc* 1995;27:1022-1032.
- Anitua E, Sanchez M, Orive G, Andia I. The potential impact of the preparation rich in growth factors (PRGF) in different medical fields. *Biomaterials* 2007;28:4551-4560.
- Anitua E, Sanchez M, Nurden AT, et al. Autologous fibrin matrices: A potential source of biological mediators that modulate tendon cell activities. *J Biomed Mater Res A* 2006;77:285-293.
- Sanchez M, Anitua E, Azofra J, Andia I, Padilla S, Mujika I. Comparison of surgically repaired Achilles tendon tears using platelet-rich fibrin matrices. *Am J Sports Med* 2007;35:245-251.
- Arnoczky SP, Anderson L, Fanelli G, Ho S, Mishra A, Sgaglione N. The role of platelet-rich plasma in connective tissue repair. *Orthopedics Today* 2009;26:29 [serial on the Internet]. Available from: www.orthosupersite.com/view.asp?rid=37598. Accessed April 4, 2009.
- Gosen T, Sluimer J. Prospective randomized study on the effect of autologous platelets injection in lateral epicondylitis compared with corticosteroid injection. Poster P25-444. Presented at: 13th Congress of the European Society of Sports Traumatology, Knee Surgery and Arthroscopy (ESSKA), Porto, Portugal, May 21-24, 2008.
- Maniscalco P, Gambera D, Lunati A, et al. The "Cascade" membrane: A new PRP device for tendon ruptures. Description and case report on rotator cuff tendon. *Acta Biomed* 2008;79:223-226.
- Filardo G, Kon E, Della Villa S, Vincentelli F, Fornasari PM, Marcacci M. Use of platelet-rich plasma for the treatment of refractory jumper's knee. *Int Orthop* in press, available online 31 July, 2009. doi:10.1007/s00264-009-0845-7.
- Sanchez M, Anitua E, Andia I. Application of autologous growth factors on skeletal muscle healing. Presented at the Second International Conference on Regenerative Medicine, Leipzig, Germany, May 18-20, 2005.
- Ishida K, Kuroda R, Miwa M, et al. The regenerative effects of platelet-rich plasma on meniscal cells in vitro and its in vivo application with biodegradable gelatin hydrogel. *Tissue Eng* 2007;13:1103-1112.
- Hirahara AM, Yamashiro K, Dunning R. Enhancing SLAP repairs with fibrin-PRP clots. Presented at the 64th Annual Meeting of the Canadian Orthopaedic Association, Whistler, British Columbia, Canada, July 3-6, 2009.
- Sanchez M, Azofra J, Anitua E, et al. Plasma rich in growth factors to treat an articular cartilage avulsion: A case report. *Med Sci Sports Exerc* 2003;35:1648-1652.
- Sanchez M, Anitua E, Azofra J, Aguirre JJ, Andia I. Intra-articular injection of an autologous preparation rich in growth factors for the treatment of knee OA: A retrospective cohort study. *Clin Exp Rheumatol* 2008;26:910-913.
- Cugat R. Platelet derived growth factors: Experience in soft tissue injuries and in joint trauma. Presented at the Seventh Biennial International Society of Arthroscopy, Knee Surgery & Orthopaedic Sports Medicine Congress, Osaka, Japan, April 5-9, 2009.
- Anitua E, Sanchez M, Nurden AT, et al. Platelet-released growth factors enhance the secretion of hyaluronic acid and induce hepatocyte growth factor production by synovial fibroblasts from arthritic patients. *Rheumatology (Oxford)* 2007;46:1769-1772.
- Saito M, Takahashi KA, Arai Y, et al. Intraarticular administration of platelet-rich plasma with biodegradable gelatin hydrogel microspheres prevents osteoarthritis progression in the rabbit knee. *Clin Exp Rheumatol* 2009;27:201-207.
- Ekdahl M, Wang JH, Ronga M, Fu FH. Graft healing in anterior cruciate ligament reconstruction. *Knee Surg Sports Traumatol Arthrosc* 2008;16:935-947.
- Mehta V, Foster D, Mandala C, Petsche T. Comparison of revision rates in autograft and allograft anterior cruciate ligament reconstruction. In: Day AS, ed. *Las Vegas: AOSSM specialty day 2009*. Las Vegas: AAOS, 2009;49.
- Carey JL, Dunn WR, Dahn DL, Zeger SL, Spindler KP. A systematic review of anterior cruciate ligament reconstruction with autograft compared with allograft. *J Bone Joint Surg Am* 2009;91:2242-2250.
- Radice F, Gutierrez V, Ibarra A, Verdugo A. Arthroscopic, histologic and MRI correlation in the maturation process of the graft in ACL reconstruction in humans. *Arthroscopy* 1998;14:S20 (Suppl 1).

35. Radice F, Yanez R, Gutierrez V, Pinedo M, Rosales J, Coda J. Uso de concentrado autologo rico en factores de crecimiento en la reconstrucción del LCA. *Rev Argent Artrosc* 2008;14: 31-40.
36. Silva A, Sampaio R. Anatomic ACL reconstruction: Does the platelet-rich plasma accelerate tendon healing? *Knee Surg Sports Traumatol Arthrosc* 2009;17:676-682.
37. Anitua E, Sanchez M, Orive G, Andia I. Delivering growth factors for therapeutics. *Trends Pharmacol Sci* 2008;29:37-41.
38. Sanchez M, Azofra J, Aizpurua B, Elorriaga R, Anitua E, Andia I. Use of autologous plasma rich in growth factors in arthroscopic surgery. *Cuad Artrosc* 2003;10:12-19.
39. Murray MM, Palmer M, Abreu E, Spindler KP, Zurakowski D, Fleming BC. Platelet-rich plasma alone is not sufficient to enhance suture repair of the ACL in skeletally immature animals: An in vivo study. *J Orthop Res* 2009;27:639-645.
40. Murray MM, Spindler KP, Ballard P, Welch TP, Zurakowski D, Nanney LB. Enhanced histologic repair in a central wound in the anterior cruciate ligament with a collagen-platelet-rich plasma scaffold. *J Orthop Res* 2007;25:1007-1017.
41. Murray MM, Spindler KP, Abreu E, et al. Collagen-platelet rich plasma hydrogel enhances primary repair of the porcine anterior cruciate ligament. *J Orthop Res* 2007;25:81-91.
42. Murray MM, Spindler KP, Devin C, et al. Use of a collagen-platelet rich plasma scaffold to stimulate healing of a central defect in the canine ACL. *J Orthop Res* 2006;24:820-830.